

Instituto de Ortopedia e Traumatologia – HC/FMUSP

Bx anterior (1142925) – Neoplasia mesenquimal fusocelular com áreas mixóides

Diagnóstico final: Sarcoma fibromixóide de baixo grau

Diagnóstico diferencial:

1. Neurofibroma mixóide
2. Fibromatose
3. Mixofibrossarcoma
4. Variante mixóide de Dermofibrossarcoma protuberans
5. Tumor maligno de bainha nervosa periférica

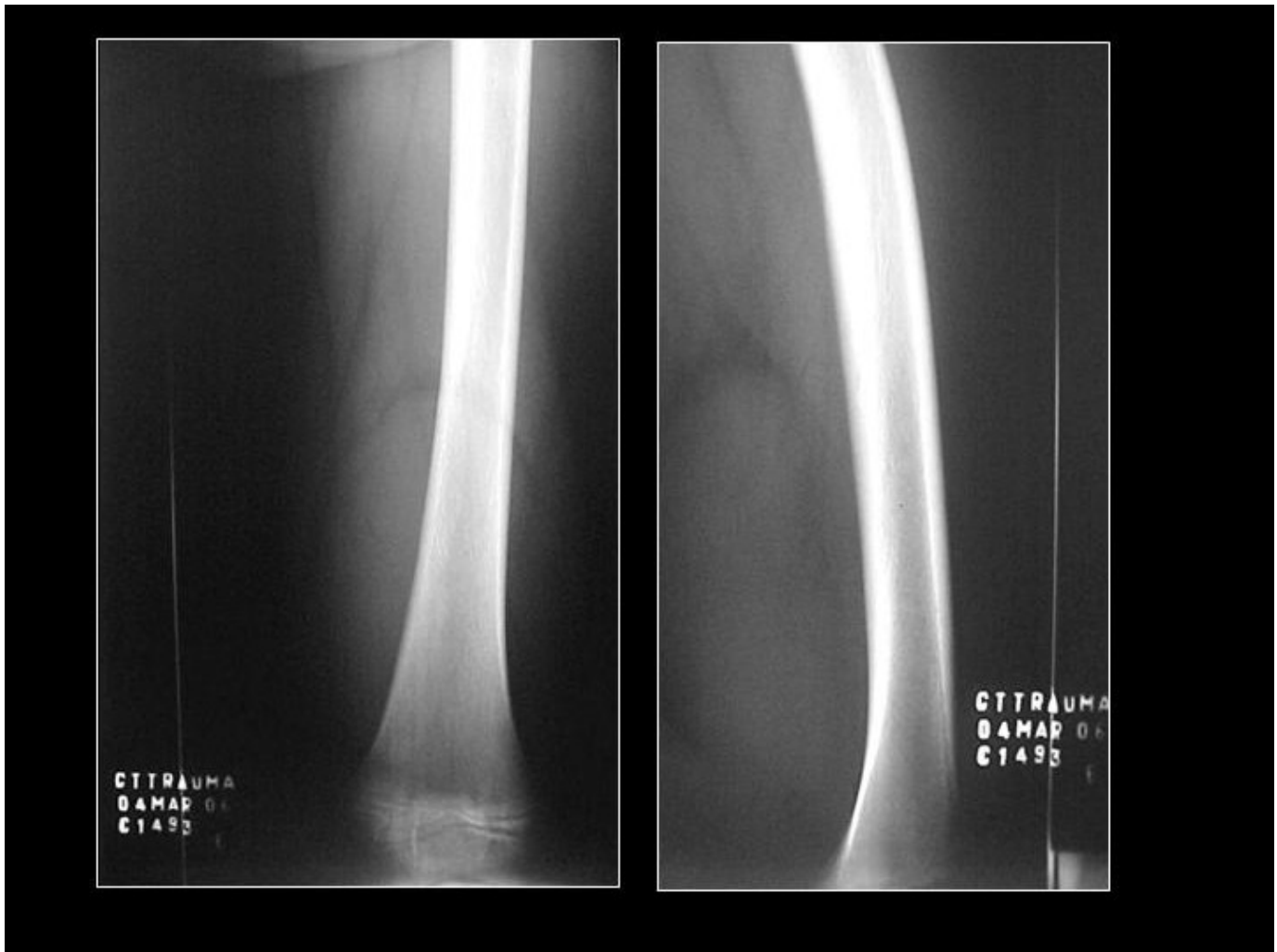Referências:

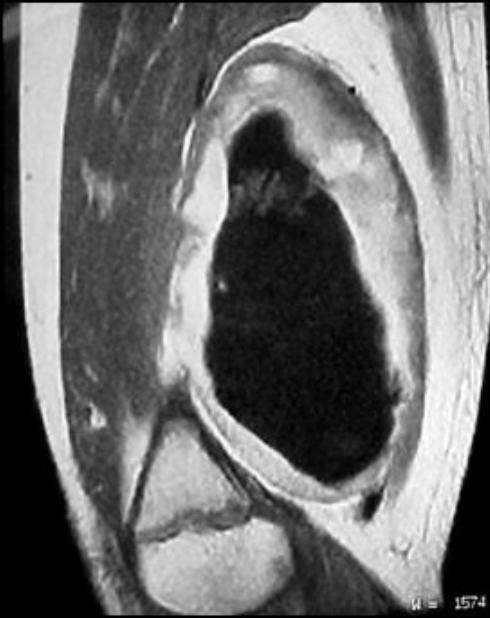
- Evans HL (1993). Low-grade fibromyxoid sarcoma. A report of 12 cases. *Am J Surg Pathol* 17:595-600.
- Folpe AL, Lane KL, Paull G, Weiss SW (2000). Low-grade fibromyxoid sarcoma and hyalinizing spindle cell tumor with giant rosettes: a clinicopathologic study of 73 cases supporting their identity and assessing the impact of high-grade areas. *Am J Surg Pathol* 24: 1353-1360.
- Shidham VB, Ayala GE, Lahaniatis JE, Garcia FU (1999). Low-grade fibromyxoid sarcoma: clinicopathologic case report with review of the literature. *Am J Clin Oncol* 22: 150-155.
- Zamecnik M, Michal M. Low-grade fibromyxoid sarcoma: A report of eight cases with histologic, immunohistochemical, and ultrastructural study. *Ann Diagn Pathol* 4:207, 2000.
- Kim, Su Young MD, Kim, Mi-Young Md, et all; Low-grade fibromyxoid sarcoma: CT, Sonography, and MR Findings in 3 cases. *J Thoracic Imaging* November 2005 20:4, p294-297.

Instituto de Ortopedia e Traumatologia – HC/FMUSP

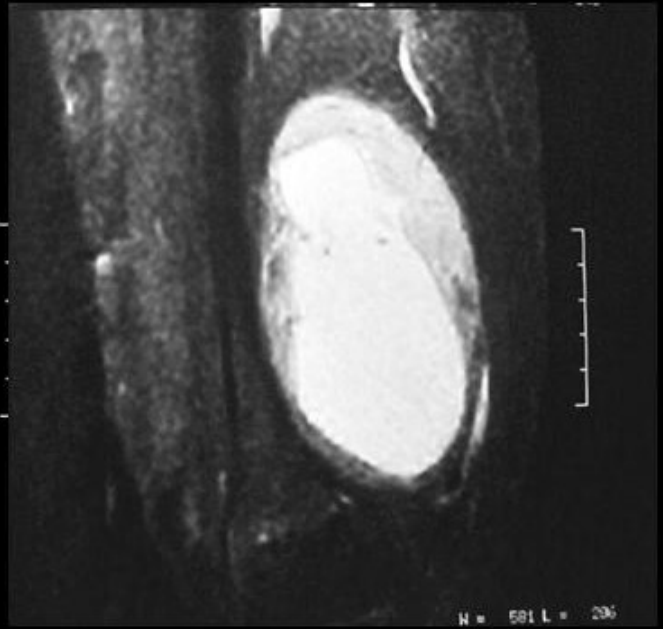Caso - 1143999

- M.M.S
- Masculino
- 9 anos
- Aumento de volume em região da coxa

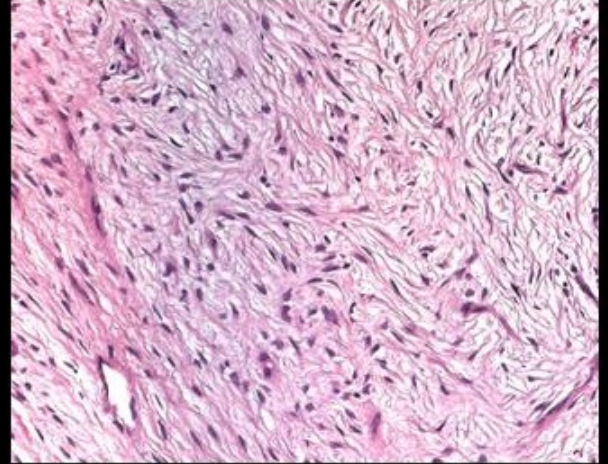
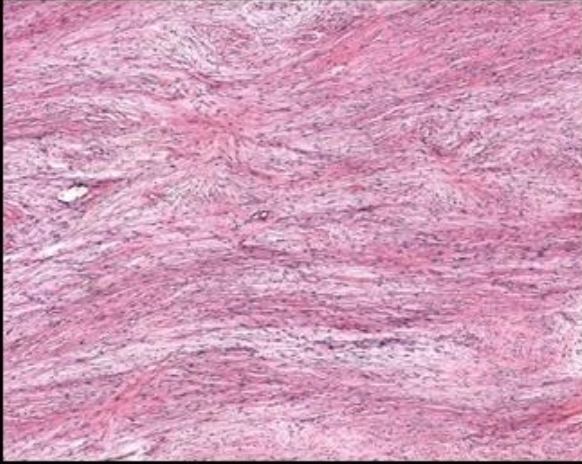


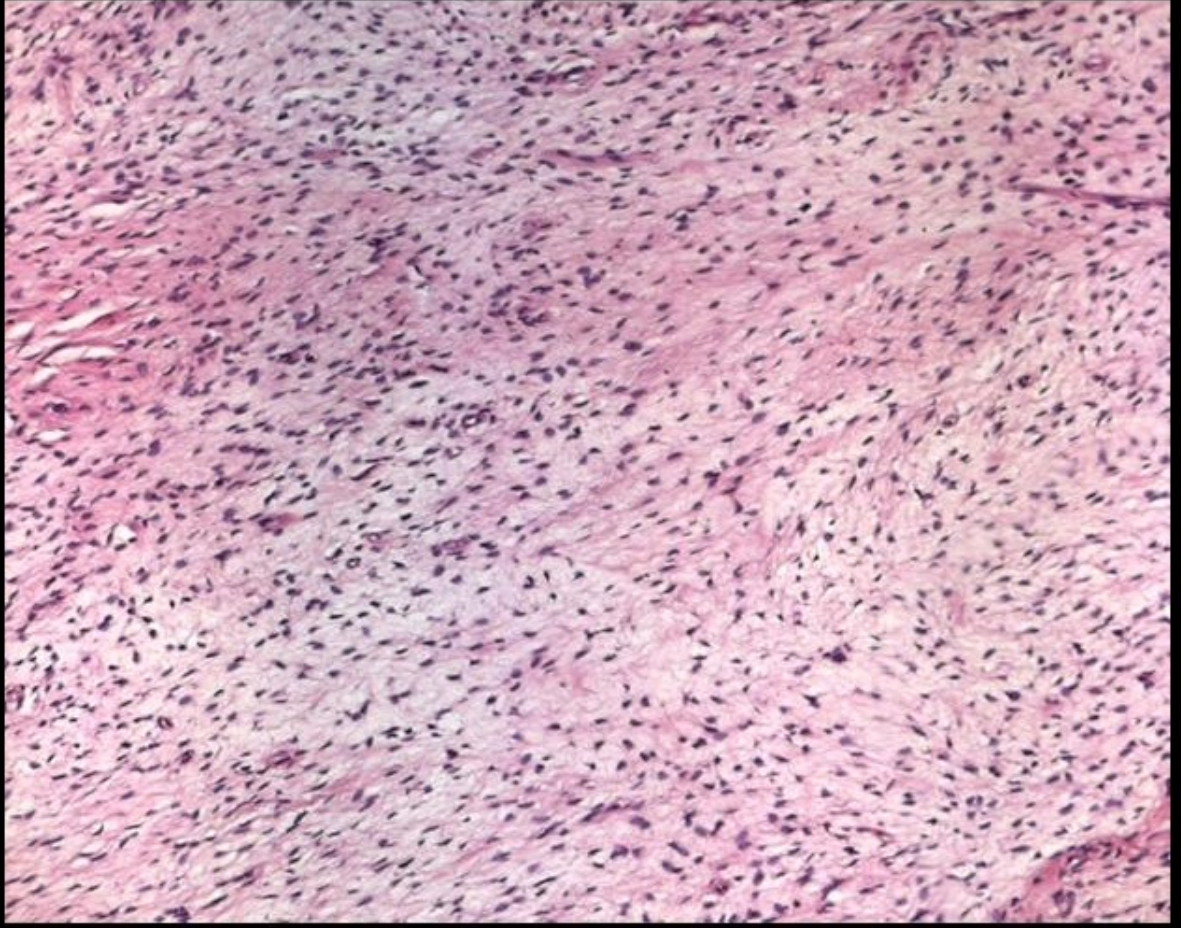


T1 contraste



T 2





This document was created with Win2PDF available at <http://www.win2pdf.com>.
The unregistered version of Win2PDF is for evaluation or non-commercial use only.
This page will not be added after purchasing Win2PDF.